Journal of
Pediatric Dentistry
DOI: 10.14744/JPD.2025.7_293
J Pediatr Dent 2026;12(1):27-36

Original Article

# Longevity of Resin Restorations in MIH Affected First Permanent Molars with and without Deproteinization: A 36- Month Randomized Controlled Trial

Mrinalini Rathore[1] Krishan Gauba[1] Ashima Goyal[1] Manoj Jaiswal[1]

[1]Department of Pedodontics and Preventive Dentistry, Oral Health Sciences Centre PGIMER, Chandigarh, India

**Address for correspondence:** Mrinalini Rathore, Ex-Junior resident, Department of Pedodontics and Preventive Dentistry, Oral Health Sciences Centre PGIMER, Chandigarh 160012, India
**E-mail:** rathoremrinalini@gmail.com

**Abstract**

**Objective:** MIH affected molars still pose a restorative challenge to the treating clinician with several authors reporting significantly higher rates of adhesive failures of resin-based restorations compared to their sound counterparts. The objective of the study is to compare the 36 months clinical and radiographic performance of direct resin restorations placed with and without prior treatment with a deproteinizing agent.

**Materials and Methods:** In this parallel group double blind randomized trial, 50 vital first permanent molars, affected with MIH and requiring restorations of at least 2 surfaces, were randomly allocated by stratified permuted block randomization to receive direct resin restorations either with or without deproteinization using 5% sodium hypochlorite (n=25 each). Clinical and radiographic evaluations of the restored molars were carried till 36 months using the USPHS criteria.

**Results:** At 36 months, overall retention rate was found to be 100% with complete elimination of any pre-existing sensitivity. Cumulative survival rates were found to be 100% in both groups.

**Conclusion:** Direct composite restorations served as an adequate restorative measure for first permanent molars affected with moderate to severe MIH where the defect was limited to two surfaces and the preparation involved removal of the defect till detection of reasonable resistance in enamel.

**Keywords:** Deproteinization, hypomineralization, MIH, MIH affected molars, restoration

## Introduction

The term molar incisor hypomineralization (MIH) is used to describe the clinical appearance of enamel hypomineralization of systemic origin affecting one or more first permanent molars (FPMs) that are associated frequently with affected incisors.[1] MIH of first permanent molars (FPMs) is a relatively common condition with a reported prevalence of 4–25 percent.[2,3] Owing to the disrupted ameloblastic function during the maturation stage of amelogenesis, the resultant enamel is qualitatively defective which readily undergoes Post Eruptive Breakdown (PEB) under masticatory forces.[4] Further the porous nature of the defective enamel makes it very sensitive to any kind of stimuli, even brushing. This results in avoidance of brushing of the affected teeth, thereby leading to plaque accumulation, early caries onset and complete breakdown of the enamel exposing the unprotected dentine.[5]

**How to cite this article:** Rathore M, Gauba K, Goyal A, Jaiswal M. Longevity of Resin Restorations in MIH Affected First Permanent Molars with and without Deproteinization: A 36- Month Randomized Controlled Trial. J Pediatr Dent 2026;12(1):27-36

OPEN ACCESS This work is licensed under a Creative Commons Attribution-NonCommercial 4.0 International License.

Based on the severity of hypomineralization, the resultant breakdown and associated symptoms, various treatment options have been suggested for managing these molars.[6] The restoration of MIH affected molars is complicated with repeated loss of restoration owing to the breakdown of hypomineralized enamel at restoration margins necessitating frequent replacements. Moreover, as the pattern of these defects usually does not conform to the normal pattern of pit and fissure caries, failure of restoration on even a single surface may warrant the replacement of the entire restoration. In fact, MIH affected molars undergo dental treatment nearly 9 times more often than non-MIH molars, and every defective tooth on an average is reportedly treated twice.[7,8] The plausible explanation for the poor bond between the enamel–resin interface is the high organic content seen in MIH affected enamel with increased proteins. This has led to similarities being drawn between the composition, treatment, and management of amelogenesis imperfecta (AI)-affected enamel and MIH- affected enamel.[9,10]

In order to overcome the complications of excessive protein content of hypomineralized teeth including MIH affected molars, deproteinization treatment prior to placement of restorations has been proposed as this potentially improves the resin-enamel bond.[11] The use of 5 percent sodium hypochlorite for deproteinization of enamel was first studied by Venezie et al[10] in teeth affected with Amelogenesis Imperfecta. The 'Bleach' pretreatment using 5 percent sodium hypochlorite can potentially have a beneficial effect on the enamel-resin interface of hypomineralized teeth as a result of its protein denaturing ability.[11–13] Various other agents viz. papain gel, bromelain enzyme, calcium hypochlorite have also been proposed for use as deproteinizing agents.[9] Drawing from the similarities between the two types of enamel-affected with Molar Incisor Hypomineralization and Amelogenesis Imperfecta, Wright postulated that a 'bleach-etch-seal' technique could be used for enhancing the resin-enamel interface and ultimately the micromechanical bonding in MIH-affected enamel.[12] The same concept has now been extended to the restoration of MIH affected teeth using composite restorations, as an attempt to improve their clinical performance.[14]

Thus, bearing in mind the suggested potential improvement in the clinical performance and retention of resin restorations in MIH affected FPMs after treatment with a deproteinizing agent (5% NaOCl), and the lack of well-designed prospective randomized controlled trials evaluating the same, the present study was planned to evaluate and compare the effect of deproteinization using 5 percent sodium hypochlorite on the longevity of resin restorations for MIH affected FPMs in 8–14 years old children. The null hypothesis for the statistical evaluation was that no difference exists in the longevity of direct resin restorations on MIH affected molars done with or without deproteinization of the tooth surface.

## Materials and Methods

The study was designed to test the null hypothesis that there is no difference in the longevity of direct resin restorations performed on MIH affected molars with or without deproteinization using 5% NaOCl. In the present parallel group double blinded randomized trial, a total of 50 permanent first molars affected with severe MIH in 35 children were restored using direct resin restorations either with or without pre-treatment with 5% sodium hypochlorite. The trial was labelled as a double blinded trial since both the participant and the investigator evaluating the restoration at different time periods were unaware of whether or not the deproteinization treatment was rendered. The pediatric dentist rendering the treatment could, however, not be blinded to the groups for obvious reasons. However, the identical appearance of the restorations and the homogeneity in all other respects apart from an additional step in the procedure made it possible to keep the evaluations of the restorations completely blinded.

The sample size calculation was based on a study conducted by Lygidakis et al[13] Based on this, the minimum sample size was found to be 36 molars at a confidence level of 95% and a significance level of 0.05 with 80% power of the study. Considering the expected 10% attrition rate of the sample a final sample of 50 was selected.

An Institutional Ethical Board approval was obtained before commencing the study (NK/4885/MDS/210) and all procedures were carried out in keeping with the guidelines laid out in the Declaration of Helsinki. The trial was registered with the Clinical Trial registry of India as well (CTRI/2019/03/018005).

**Recruitment**

Children aged 8–14 years, attending the Out-patient unit of Pediatric Dentistry, Oral Health Sciences Center, Chandigarh between August 2018 and February 2019 were screened for MIH using the criteria proposed by the European Academy of Pediatric Dentistry.[1] Children with at least one first permanent molar (FPM) exhibiting demarcated opacities with or without affected incisors were accepted as MIH affected.

FPMs were further assessed according to the following inclusion criteria: a) MIH affected FPMs that needed restoration of at least two surfaces because of post eruptive breakdown and/or carious involvement, b) MIH affected molars that had been previously restored but required replacement of the existing restoration in accordance with the first criteria, c) No clinical or radiographic sign of associated pulpal/periradicular pathology. Based on the aforementioned criteria, 50 first permanent molars (FPMs) from 35 children, were included in the study after obtaining a written informed consent from the respective parents.

**Treatment groups and randomization**

Two treatment groups were created for the investigation viz. Group A- Direct composite restoration of included FPMs after their deproteinization treatment using 5% NaOCl, and Group B- Direct composite restoration of included FPMs without subjecting them to the deproteinization treatment.

A stratified permuted block randomization sampling technique was applied using computer-generated sequence of numbers (facilitated by one of the supervisors, MJ) for the random allocation of 50 molars (divided into 9 blocks containing 4, 6, 4, 4, 8, 6, 6, 4, and 8 units, respectively) into one of the two treatment groups in the ratio of 1:1. This was done through sequentially numbered sealed opaque envelopes within the respective block envelope, by one of the supervisors (KG) ensuring that the allocation was completed from one block before moving on the next one. Each tooth was allocated its group on the day of the procedure.

**Clinical procedure**

All dental procedures were carried out by a single trained pediatric dentist (MR) under local anesthesia and rubber dam isolation. The extent of the cavity preparation was dictated by removal in entirety of the carious tissue and removal of hypomineralized enamel until reasonable resistance was detected. Following the preparation of cavity walls, calcium hydroxide liner (Septodont, France) was applied in deep portions of the preparation that were in close proximity to the pulp. This was followed by application of a protective base of Glass Ionomer Cement to compensate for the lost dentin thickness where needed.

**Restorative procedure for group A**

Following cavity preparation, the cavity walls were etched with 37 percent Phosphoric Acid (3M™ ESPE™ ScotchbondTM Etchant) for 30 seconds and then rinsed with water. The etched teeth were then air dried. For deproteinization, the etched tooth surfaces were painted with a cotton pellet soaked in 5 percent sodium hypochlorite for 60 seconds and then rinsed with water. The deproteinized surfaces were then air dried for a few seconds till a frosted appearance of the etched-deproteinized surface was evident. This was followed by application of total etch, self-priming, dentin bonding agent (3M™ ESPE™ Adper™ Single Bond 2 Adhesive) using a microbrush, which was then light cured. The teeth were then restored using incremental portions of bulk fill direct posterior composite (3M™ FiltekTM Z350XT, XT Universal Restorative) to re-establish anatomic contours of the tooth. After gross finishing of the restoration, the rubber dam was removed. An articulating paper was used to check for occlusal high points if any, which were then reduced before final finishing of the restoration. Final finishing of the restoration was carried out with composite finishing kit and burs. The restorative procedure is depicted pictorially in Figure 1.

**Restorative procedure for group B**

The restorative procedure was identical to that followed for Group A, barring the step of deproteinization using 5 percent sodium hypochlorite. The final restorations were similarly checked for occlusion and finished.

**Evaluation**

Two blinded, calibrated evaluators (KG and MJ) carried out the clinical and radiographic evaluations of the restorations. The first post-restoration recall was at 1 week, primarily for assessment of any immediate discomfort and hypersensitivity resolution. At the subsequent recall appointments at 3, 6, 12, 18, 24 and 36 months, restorations were scored for their retention, marginal integrity, marginal discoloration, anatomic form, secondary caries and hypersensitivity using the modified United States Public Health Services (USPHS) criteria outlined in Table 1.[15] For each criterion, Alpha indicated the greatest degree of clinical acceptability, Bravo represented clinically acceptable scores while Charlie was regarded as a clinically unacceptable score and its assignment to any restoration would have rendered the same a failure warranting re-treatment. Plaque scores and gingival health were assessed using the Loe and Silness index (1963) and the Silness and Loe index (1964), respectively. Sequential radiographic assessment using Intra-oral Peri-apical radiographs was also carried out to monitor continuation of root development and peri-apical health as signs of tooth vitality. Of all the parameters, retention of the restorations formed the primary outcome whilst the rest formed part of the secondary outcomes.

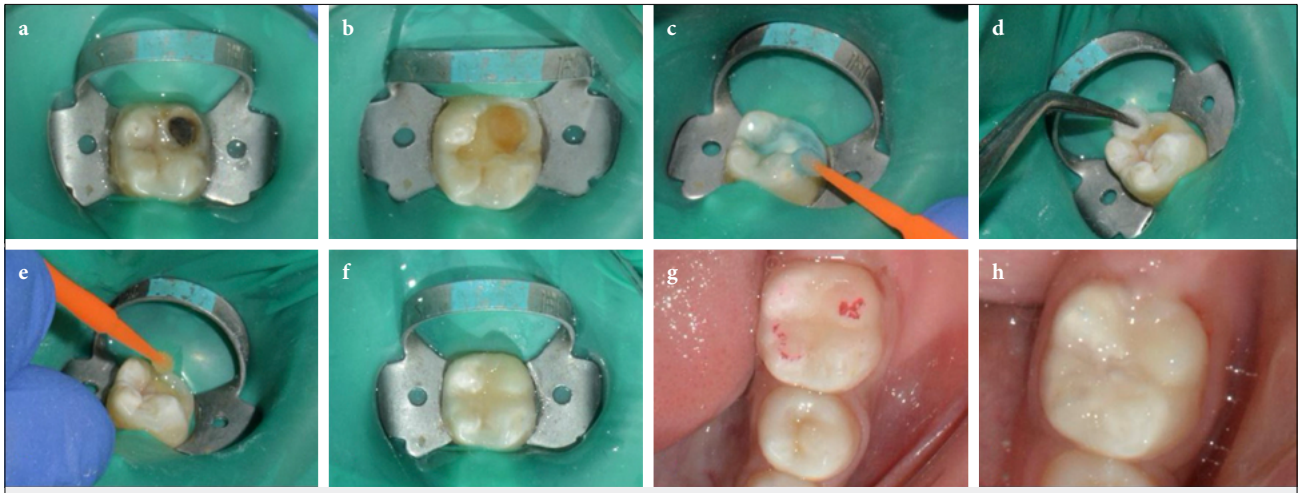


**Figure 1.** Stepwise procedure followed for restoring the MIH affected Molars in group A; (a) Isolated MIH affected molar with carious defect. (b) Removal of carious and hypomineralized dental tissue till detection of reasonable resistance. (c) Application of acid etchant followed by rinsing. (d) Application of 5% Sodium Hypochlorite-soaked cotton pellet for 1 minute followed by rinsing. (e) Application of bonding agent to etched and deproteinized tooth surface. (f) Restoration with direct composite resin. (g) Reduction of occlusal high points and final finishing of the restoration (h) Restoration at 12 mo follow up

**Statistical analysis**

Inter-examiner reliability for the two evaluators (KG and MJ) was assessed to be excellent upon the re-evaluation of 15 restorations (Cohen's Kappa coefficient score of 0.8). Data from a single evaluator was then used to carry out the statistical analysis.

Statistical analyses were performed using IBM SPSS Statistics for Windows (Version 25.0. Armonk, NY: IBM Corp.). Results on continuous data are presented as Mean & SD and categorical measurements are presented as Frequency & Percentage. Categorical variables were compared between two groups using Chi-square/Fisher exact test and quantitative using the Mann-Whitney U test. $p<0.05$ was considered statistically significant.

## Results

A total of 72 permanent first molars affected with moderate to severe MIH (49 children) were assessed for eligibility between the period of August 2018 and February 2019. Of these, 36 children (n=19 males, 17 females) with 50 affected molars in the age range of 8–14 years (mean 10.2 years) were finally included (Fig. 2). Factors necessitating restorations were the presence of PEB (n=47, 94%), atypical caries (n=43, 86%), defective previous restorations (n=10, 20%) and sensitivity to cold in the affected tooth (n=46, 92%). The unit of allocation was the tooth and not the child. The maximum number of either type of restorations placed in a single child were 4 (in 1 child). Two children received restorations in three molars and 7 children received restorations in two of their four first permanent molars. Table 2 outlines the demographic characteristics of the study sample in both groups. The recall rate of children was 100% (36 children) at 12 months, 97.2% (35/36 children, 49/50 restored FPMs) at 24 months as one child was lost to follow-up in Group A, and 91.6% (33/36, 47/50 restored FPMs) at 36 months as two children from group B failed to report for follow-up thereafter. All the cases lost to follow up were ones that had received restorations in only one of their four FPMs. The number of children and restored FPMs included for the final analysis at 36 months was 33 and 47 respectively (Fig. 2).

Table 3 lists the cavity design for each of the patient enrolled in either of the two groups in terms of the surface involved viz. Occlusal (O), Buccal (B), Palatal/Lingual (P), Mesial (M) and/or Distal (D). The OB cavity design was the most common in both groups separately - Group A- 60%, n=15/25; Group B – 44%, n=11/25; p-value=0.43 and in the total sample (52%; n=26/50). The difference in the number of molars with OB cavity design over the other combinations of surfaces restored was found to be statistically significant ($p<0.05$).

Table 4 compiles the results of the scores allotted to the restorations according to USPHS criteria. The restorations in the two groups did not show any clinical or radiographic differences at the 3- and 6-months period. For anatomic form, scores changed from Alpha to Bravo after 12 months in 1 FPM in Group A and in 4 FPMs in Group B (p=0.34). These scores, however, did not worsen at subsequent reviews. Similarly, Bravo scores

**Table 1.** Modified USPHS criteria

| | Alpha | Bravo | Charlie |
|---|---|---|---|
| Retention | No loss of retention | Partial loss or mobile restoration | Complete loss of retention |
| Marginal adaptation | No catch or crevice | Catch but no exposure | Explorer reaches DEJ |
| Marginal discoloration | Matches adjacent tooth structure | Slight mismatch with adjacent tooth structure | Strong mismatch with adjacent tooth structure |
| Anatomic form | Restoration is contiguous with the original tooth anatomy | Slight discontinuity, clinically acceptable | Discontinuous, failure |
| Surface texture | Surface of restoration similar to enamel | Surface of restoration gritty | Surface of restoration pitted and coarse |
| Secondary caries | No caries present | – | Caries present |
| Post-operative hypersensitivity | No sensitivity | Mild sensitivity with no pain, no retreatment required. | Sensitivity with severe pain, retreatment required |

USPHS: United States Public Health Services, DEJ: Dentinoenamel junction

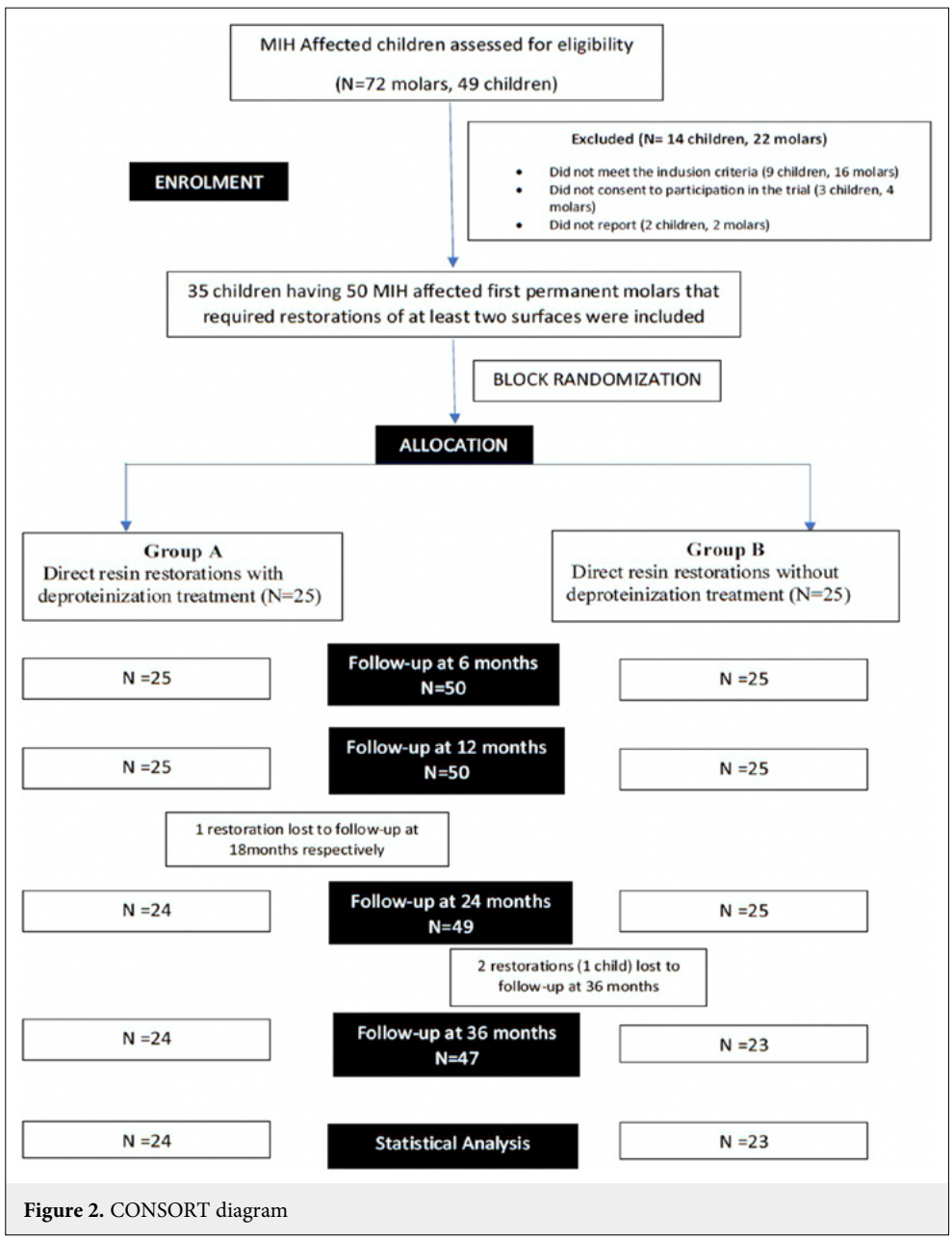


**Figure 2.** CONSORT diagram

**Table 2.** Comparative evaluation of baseline parameters

| Baseline parameters | Group A | Group B |
|---|---|---|
| Mean age | 9.92 | 9.68 |
| Average DMFT+deft | 7.56 | 8.04 |
| Brushing frequency | 2.04 | 2.08 |
| Hypomineralized molars distribution | | |
| Maxillary | | |
| 16 | 3 | 7 |
| 26 | 9 | 6 |
| Total | 12 | 13 |
| Mandibular | | |
| 36 | 5 | 6 |
| 46 | 8 | 6 |
| Total | 13 | 12 |
| Pre-treatment status | | |
| MIH affected molars | 25 | 25 |
| MIH affected along with caries | 22 | 21 |
| Restored hypomineralized molars requiring replacement | 7 | 4 |

DMFT: Decayed, missing, filled teeth, MIH: Molar incisor hypomineralization

were recorded for marginal adaptation of 1 restoration in Group A and for 4 restorations in Group B.

2 restorations in Group B began showing marginal discoloration warranting Bravo scores at 12 months. At the end of 36 months, this number had increased to 4. Only 1 restoration in Group A received a Bravo score at 24 months which stayed stable till the end of 36 months (p=0.18 at 36 mo). No restoration received a Charlie score.

**Table 3.** Cavity design for each of the patient enrolled in either of the two groups in terms of the surface involved

| Cavity design | Group A | Group B |
|---|---|---|
| | n (%) | n (%) |
| OB | 15 | 11 |
| OP | 5 | 7 |
| OBD | 3 | 4 |
| OPD | 4 | 1 |
| OBM | 0 | 1 |
| OD | 0 | 1 |

OB: Occlusal-buccal, OP: Occlusal-palatal, OBD: Occlusal-Buccal-distal, OPD: Occlusal palatal distal, OBM: Occlusal-buccal-mesial, OD: Occlusal-distal

Surface texture was scored to be consistently uniform till the end of 36 months in both the groups. None of the restored teeth in either group was found to develop any evidence of secondary caries.

Pre-operatively, 24/25 teeth in Group A and 22/25 teeth in Group B demonstrated moderate-severe grades of hypersensitivity. Hypersensitivity was found to have resolved in all the restored teeth at the 1-week recall. Thereafter, all the restored teeth continued to remain free of hypersensitivity till 24 months. At 36 months, only one tooth in group A demonstrated mild sensitivity (Bravo score) upon testing with cold air, however it did not warrant re-treatment. The difference of scores for any parameter between the two groups were not found to be statistically significant (p>0.05). The sequential radiographs recorded demonstrated continuous root growth and did not show signs of periapical disease in any of the restored teeth at any point of evaluation (Fig. 3).

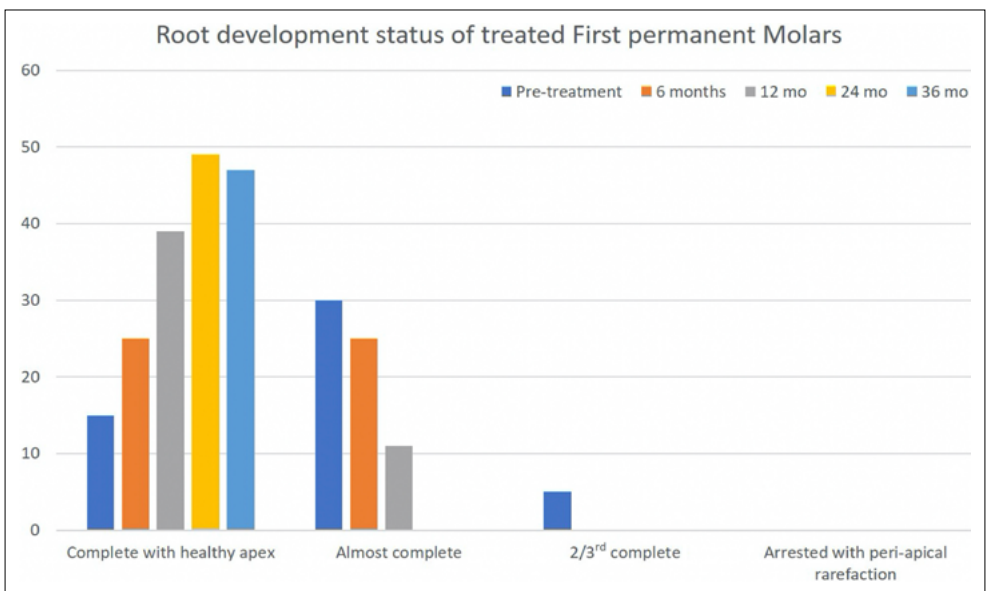


**Figure 3.** Root development status of restored molars

**Table 4.** Clinical results of restored teeth in both groups evaluated per the modified USPHS criteria

| Evaluation parameters | Time interval | | | | | | | | | |
|---|---|---|---|---|---|---|---|---|---|---|
| | Baseline | | 6 months | | 12 months | | 24 months | | 36 months | |
| | Group A | Group B | Group A | Group B | Group A | Group B | Group A | Group B | Group A | Group B |
| Retention | | | | | | | | | | |
| Alpha | 25 | 25 | 25 | 25 | 25 | 25 | 24 | 25 | 24 | 23 |
| Bravo | 0 | 0 | 0 | 0 | 0 | 0 | 0 | 0 | 0 | 0 |
| Charlie | 0 | 0 | 0 | 0 | 0 | 0 | 0 | 0 | 0 | 0 |
| p | 1.00 | 1.00 | 1.00 | 1.00 | 1.00 | | | | | |
| Marginal adaptation | | | | | | | | | | |
| Alpha | 25 | 25 | 25 | 25 | 25 | 24 | 23 | 21 | 22 | 19 |
| Bravo | 0 | 0 | 0 | 0 | 0 | 1 | 1 | 4 | 2 | 4 |
| Charlie | 0 | 0 | 0 | 0 | 0 | 0 | 0 | 0 | 0 | 0 |
| p | 1.00 | 1.00 | 0.49 | 0.35 | 0.41 | | | | | |
| Marginal discoloration | | | | | | | | | | |
| Alpha | 25 | 25 | 25 | 25 | 25 | 23 | 23 | 23 | 23 | 19 |
| Bravo | 0 | 0 | 0 | 0 | 0 | 2 | 1 | 2 | 1 | 4 |
| Charlie | 0 | 0 | 0 | 0 | 0 | 0 | 0 | 0 | 0 | 0 |
| p | 1.00 | 1.00 | 0.48 | 1.00 | 0.18 | | | | | |
| Anatomic form | | | | | | | | | | |
| Alpha | 25 | 25 | 25 | 25 | 25 | 25 | 23 | 21 | 23 | 19 |
| Bravo | 0 | 0 | 0 | 0 | 0 | 0 | 1 | 4 | 1 | 4 |
| Charlie | 0 | 0 | 0 | 0 | 0 | 0 | 0 | 0 | 0 | 0 |
| p | 1.00 | 1.00 | 1.00 | 0.35 | 0.18 | | | | | |
| Surface texture | | | | | | | | | | |
| Alpha | 25 | 25 | 25 | 25 | 25 | 25 | 24 | 25 | 24 | 23 |
| Bravo | 0 | 0 | 0 | 0 | 0 | 0 | 0 | 0 | 0 | 0 |
| Charlie | 0 | 0 | 0 | 0 | 0 | 0 | 0 | 0 | 0 | 0 |
| p | 1.00 | 1.00 | 1.00 | 1.00 | 1.00 | | | | | |
| Secondary caries | | | | | | | | | | |
| Alpha | 25 | 25 | 25 | 25 | 25 | 25 | 24 | 25 | 24 | 23 |
| Bravo | 0 | 0 | 0 | 0 | 0 | 0 | 0 | 0 | 0 | 0 |
| Charlie | 0 | 0 | 0 | 0 | 0 | 0 | 0 | 0 | 0 | 0 |
| p | 1.00 | 1.00 | 1.00 | 1.00 | 1.00 | | | | | |
| Hypersensitivity | | | | | | | | | | |
| Alpha | 1 | 3 | 25 | 25 | 25 | 25 | 24 | 25 | 23 | 23 |
| Bravo | 13 | 9 | 0 | 0 | 0 | 0 | 0 | 0 | 1 | 0 |
| Charlie | 11 | 13 | 0 | 0 | 0 | 0 | 0 | 0 | 0 | 0 |
| p | 0.36 | 1.00 | 1.00 | 1.00 | 1.00 | | | | | |

USPHS: United States Public Health Services

## Discussion

Hypomineralized young permanent molars, have attracted a lot of interest from pediatric dentists, the world over, owing to the associated clinical problems particularly the hypersensitivity, post-eruptive breakdown and the resultant restorative dilemma they pose. [2,3,6,7] Several strategies have been suggested in literature to facilitate predictable longevity of restorations in MIH affected molars. Several authors have investigated

a spectrum of direct restorative materials for these hypomineralized molars including traditional restorative Glass Ionomer Cement (GIC), Resin Modified GIC, Hybrid GIC and Composite resin restorations.[6,13,16–18] Direct restorations are indicated in MIH affected FPMs where the defect involves 2–3 surfaces, with composite resin restorations showing the best results in terms of longevity compared to all other direct restorative options investigated.[6,8,19] These restorations, however, are not free from concerns regarding inevitable restorative failures owing to the breaches at the tooth-restoration interface.[13,14,20] These failures are attributed to the lower inorganic and higher protein content in the MIH affected enamel along with greater porosity and cracks evident in its ultrastructure.[21,22] These aberrations in MIH affected molars are responsible for atypical etching patterns, limited inter-rod dissolution, high inter-crystal porosity, and poor microtag formation that ultimately translate to an inferior bond strength with resin restorations than what their sound counterparts exhibit.[21,23]

The concept of deproteinizing hypomineralized enamel prior to resin restorations is thus based on the theory that removing the excess protein will lead to better adhesion. First suggested by Venezie et al[10] to improve the bond strength of orthodontic brackets to AI affected enamel, deproteinization using 5% Sodium Hypochlorite was then investigated in MIH affected molars by Gandhi et al[24] to aid in retention of pit and fissure sealants, but with no significant improvement.[10,24] Sonmez et al[14], were the first to investigate deproteinization as a pre-treatment for MIH affected enamel receiving resin restorations. They studied the effect of deproteinization on several cavity designs and reported a significant improvement in the retention of composite resin restorations placed after deproteinization only when the restoration margins rested on hypomineralized enamel. Hitherto, there are no absolute guidelines for cavity preparation in such teeth. Digressing from the recommendations by Fayle et al[25] to limit tooth structure removal to only softened enamel, William et al[5], endorsed the more invasive approach of removing all hypomineralized structure till sound enamel surfaces were reached. In our trial we set out to investigate the longevity of resin restorations in moderate to severe MIH affected first permanent molars placed with and without deproteinization using 5% Sodium Hypochlorite following cavity designs such that the hypomineralized tissue was removed only till resistance was met by the cutting bur. In this way, the final margins would rest on hypomineralized but not structurally compromised enamel.

In the bleach-etch-seal technique by Gandhi et al[24], the tooth surface was treated with 5% Sodium Hypochlorite and then etched. However in our study, the tooth surfaces were first etched with 37% phosphoric acid and then subjected to 5% Sodium Hypochlorite solution via a soaked cotton pellet for 1 minute. This was similar to the approach followed by Sonmez et al[14] and is based on the theory that acid etching the tooth surface to be bonded exposes its collagen framework thus facilitating removal of the excessive protein by the deproteinizing agent.

Upon completion of the restorations, all patients were recalled after a week's interval and assessed for any complaints. Hypersensitivity was the most commonly associated symptom with these molars at presentation. All 50 teeth, irrespective of the treatment received, were found to be free from sensitivity to cold air at their one-week follow-up. At the end of the study, 1 patient in Group B and 2 patients in Group A were lost to follow up at 24 and 36 months respectively. Two of these 3 patients moved out of the city and thus could not visit but they were followed up till 36 months telephonically and reported no signs of restoration loss or irreversible pulpal damage. 1 patient could not be contacted at all for the 36-month follow-up visit.

In terms of overall longevity, we found no significant difference between the restorations in the two treatment groups. No restoration in either group was lost till the end of 36 months. Retention was found to be 100% in both groups. Not one of the restorations in our study was found to be a failure as per the modified USPHS criteria used, nor did any warrant replacement, however, there were differences in clinical performance between the two groups which became evident after 24 months. Although statistically insignificant, a greater number of restorations were found to deteriorate in terms of marginal integrity, color match and anatomic form in the group that did not receive deproteinization. Sonmez et al[14] reported significantly inferior parameters in resin restorations done without deproteinization compared to those restored with deproteinization when the initial cavity design did not remove all the hypomineralized dental tissue. Interestingly, they found that with deproteinization the restorations exhibited similar clinical performance despite the two different approaches of cavity preparation viz removal of the entire hypomineralized dental tissue so that restoration margins rest on sound enamel versus removal of hypomineralized enamel only till resistance to the bur is met.

### Limitations

The major limitation to the study, and the technique is the subjectivity of the removal of hypomineralized tissue since it depends on the operator's proprioception.

## Conclusion

- Direct composite resin restorations are a good restorative option for MIH affected molars requiring restoration of 2–3 surfaces to prevent debilitative outcomes that result from rapid breakdown and subsequent carious involvement of unrestored MIH affected molars.
- Our results accepted the null hypothesis proposed at the onset of the study for this particular follow-up period as no difference was found to exist in the longevity of direct resin restorations on MIH affected molars done with or without deproteinization of the tooth surface.
- Addressing the dilemma of initial cavity preparation, our study suggests that removing the MIH affected tissue till resistance to the bur is met seems to be enough for the restoration margins to support the oncoming restoration.
- Deproteinizing these cut surfaces after etching and prior to bonding an adhesive resin may aid in improving longevity of these restorations, particularly the integrity of the restoration margins. The fact that this simple pre-treatment with a readily available Sodium Hypochlorite solution may help in enhancing the performance of resin restorations in MIH affected molars while giving allowance for minimally-invasive cavity designs, warrants the need for longer observation of these restores molars and further clinical investigations in this field to draw more conclusive evidence-based results.

#### Disclosures

**Ethics Committee Approval:** The study was approved by the Institutional Ethical Board (no: NK/4885/MDS/210).

**Informed Consent:** Informed consent was obtained from all participants.

**Conflict of Interest Statement:** The authors have no conflicts of interest to declare.

**Funding:** The authors acknowledge the partial funding by the Indian Council of Medical Research (ICMR) (No.3/2/Jan. 20I8/PC-Thesis-HRD) based on merit of the submitted protocol.

**Use of AI for Writing Assistance:** No AI technologies utilized.

**Peer-review:** Externally peer-reviewed.

## References

1. Weerheijm KL. Molar incisor hypomineralisation (MIH). Eur J Paediatr Dent 2003;4:114–20.
2. Lygidakis NA, Wong F, Jalevik B, Vierrou AM, Alaluusua S, Espelid I. Best clinical practice guidance for clinicians dealing with children presenting with molar-incisor hypomineralisation (MIH). An EAPD policy document. Eur Arch Paediatr Dent 2010;11(2):75–81.
3. Lygidakis NA. Treatment modalities in children with teeth affected by molar-incisor enamel hypomineralisation (MIH): A systematic review. Eur Arch Paediatr Dent 2010;11:65–74.
4. Weerheijm KL, Jalevik B, Alaluusua S. Molar incisor hypomineralisation. Caries Res 2001;35:390–1.
5. William V, Messer LB, Burrow MF. Molar incisor hypomineralization: Review and recommendations for clinical management. Pediatr Dent 2006;28:224–32.
6. Lygidakis NA, Garot E, Somani C, Taylor GD, Rouas P, Wong FSL. Best clinical practice guidance for clinicians dealing with children presenting with molar-incisor-hypomineralisation (MIH): An updated European Academy of Paediatric Dentistry policy document. Eur Arch Paediatr Dent 2022;23(1):3–21.
7. Kotsanos N, Kaklamanos EG, Arapostathis K. Treatment management of first permanent molars in children with molar-incisor hypomineralisation. Eur J Paediatr Dent 2005;6(4):179–84.
8. Almuallem Z, Busuttil-Naudi A. Molar incisor hypomineralisation (MIH) – an overview. Br Dent J 2018;2018:814.
9. Hasija P, Sachdev V, Mathur S, Rath R. deproteinizing agents as an effective enamel bond enhancer-An *in vitro* study. J Clin Pediatr Dent 2017;41(4):280–3.
10. Venezie RD, Vadiakas G, Christensen JR, Wright JT. Enamel pretreatment with sodium hypochlorite to enhance bonding in hypocalcified amelogenesis imperfecta: Case report and SEM analysis. Pediatr Dent 1994;16(6):433–6.
11. Saroglu I, Aras S, Oztas D. Effect of deproteinization on composite bond strength in hypocalcified amelogenesis imperfecta. Oral Dis 2006;12(3):305–8.
12. Wright JT. The etch-bleach-seal technique for managing stained enamel defects in young permanent incisors. Pediatr Dent 2002;24:249–52.
13. Lygidakis NA, Chaliasou A, Siounas G. Evaluation of composite restorations in hypomineralised permanent molars: A four year clinical study. Eur J Paediatr Dent 2003;4(3):143–8.
14. Sonmez H, Saat S. A clinical evaluation of deproteinization and different cavity designs on resin restoration performance in MIH-affected molars: Two-year results. J Clin Pediatr Dent 2017;41(5):336–42.
15. Cvar JF, Ryge G. Reprint of criteria for the clinical evaluation of dental restorative materials. 1971. Clin Oral Investig 2005;9(4):215–32.
16. Fragelli CMB, Souza JF, Jeremias F, Cordeiro RCL, Santos-Pinto L. Molar incisor hypomineralization (MIH): Conservative Treatment management to restore affected teeth. Braz Oral Res 2015;29(1):1–7.
17. Al Zraikat H, Palamara JE, Messer HH, Burrow MF, Reynolds EC. The incorporation of casein phosphopeptide-amorphous calcium phosphate into a glass ionomer cement. Dent Mater 2011;27(3):235–43.
18. Ghanim A, Silva MJ, Elfrink MEC, Lygidakis NA, Mariño RJ, Weerheijm KL, et al. Molar incisor hypomineralisation (MIH) training manual for clinical field surveys and practice. Eur Arch Paediatr Dent 2017;18:225–42.

19. Elhennawy K, Schwendicke F. Managing molar-incisor hypomineralization: A systematic review. J Dent 2016;55:16–24.

20. De Souza JF, Fragelli CB, Jeremias F, Paschoal MAB, Santos-Pinto L, de Cassia Loiola Cordeiro R. Eighteen-month clinical performance of composite resin restorations with two different adhesive systems for molars affected by molar incisor hypomineralization. Clin Oral Investig 2017;21(5):1725–33.

21. Bozal CB, Kaplan A, Ortolani A, Cortese SG, Biondi AM. Ultrastructure of the surface of dental enamel with molar incisor hypomineralization (MIH) with and without acid etching. Acta Odontol Latinoam 2015;28(2):192–8.

22. Farah RA, Monk BC, Swain MV, Drummond BK. Protein content of molar-incisor hypomineralisation enamel. J Dent 2010;38(7):591–6.

23. Ekambaram M, Yiu CKY. Bonding to hypomineralized enamel – A systematic review. Int J Adhes Adhes 2016;69:27–32.

24. Gandhi S, Crawford P, Shellis P. The use of a 'bleach-etch-seal' deproteinization technique on MIH affected enamel. Int J Paediatr Dent 2012;22(6):427–34.

25. Fayle SA. Molar incisor hypomineralisation: Restorative management. Eur J Paediatr Dent 2003;4(3):121–6.