Journal of
Pediatric Dentistry
DOI: 10.14744/JPD.2025.6_283
J Pediatr Dent 2026;12(1):57-62

Case Report

Neonatal Tooth in A Newborn - Case Report

Lucas Fernando Oliveira Tomáz Ferraresso[1] Tatiane Garcia[1] Gabriela Fleury Seixas[2] Cássia Cilene Dezan[2] Farli Aparecida Carrilho Boer[2]

[1]Department of Pediatric Dentistry and Public Health, School of Dentistry, São Paulo State University (UNESP), São Paulo, Brazil

[2]Department of Oral Medicine and Pediatric Dentistry, State University of Londrina (UEL), Londrina, Brazil

Address for correspondence: Lucas Fernando de Oliveira Tomáz Ferraresso, Department of Pediatric Dentistry and Public Health, School of Dentistry, São Paulo State University (UNESP), R. José Bonifácio, 1193 - Vila Mendonca, Araçatuba - SP, 16015-050, Brazil
E-mail: lucas.ferraresso@unesp.br

Abstract

Neonatal teeth are developmental dental anomalies that can be defined as those that erupt in the first 30 days of extrauterine life. This early eruption can lead to breastfeeding difficulties, ulcers on the tongue, and a risk of aspiration and/or swallowing. The objective of this study was to report a clinical case of neonatal teeth in a newborn, as well as the diagnosis and therapeutic approach adopted. A 20-day-old female Caucasian neonate attended the Pediatric Dental Emergency Care Service of the Infant Specialties Clinic of the Baby Clinic of the State University of Londrina (UEL) due to tooth eruption 10 days ago and difficulty breastfeeding. The intraoral physical examination revealed the presence of a tooth compatible with the lower left central incisor, presenting a hypoplastic structure, soft tissue insertion, and a severe mobility. The radiographic examination showed an image compatible with the aforementioned tooth from the normal series of deciduous dentitin and absence of root development. Given the observed dental characteristics, the chosen approach was extraction. It is concluded that clinical and radiographic conditions are fundamental for the assertive diagnosis and therapeutic planning of neonatal teeth, allowing the prevention of damage to maternal health during breastfeeding or early weaning, in addition to reducing the risk of more serious complications to the health of the newborn, such asbroncho aspiration.

Keywords: Infant, natal teeth, newborn, tooth extraction

Introduction

The process of dental eruption of deciduous teeth into the oral cavity generally, begins around six months of age.[1] This phenomenon represents an important milestone in the functional and psychological development of the infant, as well as an event of emotional impact for legal guardians (Cunha et al[2]). However, in certain situations, the eruption chronology may be altered, with the early emergence of teeth in the oral cavity.

Among the most frequently observed dental development anomalies, natal teeth (NT) stand out, defined as those present in the oral cavity at birth. In turn, neonatal teeth (NNT) correspond to those that erupt during the first 30 days of extrauterine life.[2,3] The prevalence of DN and NND is estimated at 34,55:10,000 and 4,52:10,000 births, respectively.[4] Several factors may be related to the etiology and early tooth eruption, including the superficial position of the tooth germ, heredity, poor maternal health, nutritional deficiencies, intrauterine exposure to environmental toxins, endocrine disorders, infections and febrile episodes during pregnancy, among others.[2–5]

As a consequence of the manifestation of NT and NNT, significant structural and functional alterations, includ-

How to cite this article: Ferraresso LFOT, Garcia T, Seixas GF, Dezan CC, Boer FAC. Neonatal Tooth in A Newborn - Case Report. J Pediatr Dent 2026;12(1):57-62

OPEN ACCESS This work is licensed under a Creative Commons Attribution-NonCommercial 4.0 International License.

ing hypoplastic dental structural content, soft tissue insertion, poor root development, increased mobility, and risk of aspiration or accidental swallowing, may be present.[3,6,7] In addition to these characteristics, discomfort may occur during breastfeeding, as well as the appearance of traumatic ulcers in the maternal breast and in the newborn's lingual belly. [2,8,9] Therefore, the identification of NT or NNT requires, without exception, an accurate diagnosis and the choice of the most appropriate therapeutic approach. The first option for the treatment of NT and NNT should always be conservative, avoiding extractions whenever possible.[10] In cases where maintenance of the tooth in the oral cavity is indicated, it is essential to remove possible traumatic agents, which can be done by smoothing the cutting edges using sandpaper strips or polishing discs. This approach aims to prevent the main complication associated with the preservation of these teeth: Riga-Fede disease. However, when the prognosis is unfavorable, extraction is indicated.[7,11]

Considering the scarcity of available literature on natal and neonatal teeth, the present study aimed to report a clinical case involving the presence of a neonatal tooth, addressing the diagnostic process and the therapeutic approach adopted.

Case Report

A 20-day-old Caucasian female infant was brought to the Pediatric Dental Emergency Care Service of the Pediatric Specialties Clinic of the Baby Clinic of the State University of Londrina (UEL), accompanied by her legal guardians, after a referral from a Primary Health Care Unit. The chief complaint reported by the guardians was the recent eruption of a tooth approximately 10 days ago, which was causing difficulties during breastfeeding. During the medical history, the guardians stated that both the pregnancy and delivery were uneventful and that the infant had no systemic conditions to date. They also reported that there were no teeth present at birth and denied any family history of natal, neonatal, or supernumerary teeth. Intraoral examination revealed the presence of a tooth in the region of the mandibular left central incisor. The tooth was hypoplastic and immature, with severe mobility (Fig. 1a, b). Radiographic evaluation, performed using the Mannkopf technique, revealed an image consistent with a normal primary tooth (tooth 81) and soft tissue insertion (Fig. 2).

Based on the clinical and radiographic findings, a diagnosis of neonatal tooth was established, and the clinical team determined the treatment plan for extraction.

For legal and ethical reasons, parents/guardians were fully informed about the procedure and its potential risks, and informed consent was obtained for outpatient tooth extraction. The procedure began with the application of a topical anesthetic ointment containing prilocaine and lidocaine (EMLA® 5% – Aspen Pharma Indústria Farmacêutica Ltda., Serra, Espírito Santo, Brazil) to the mucosa surrounding the tooth, with an application time of two minutes.

Subsequently, terminal infiltration anesthesia was performed with a 2% lidocaine solution with phenylephrine 1:100,000 (Alphacaine – DFL Indústria e Comércio S.A., Rio de Janeiro, Brazil) (Fig 3a, b). The tooth was excised

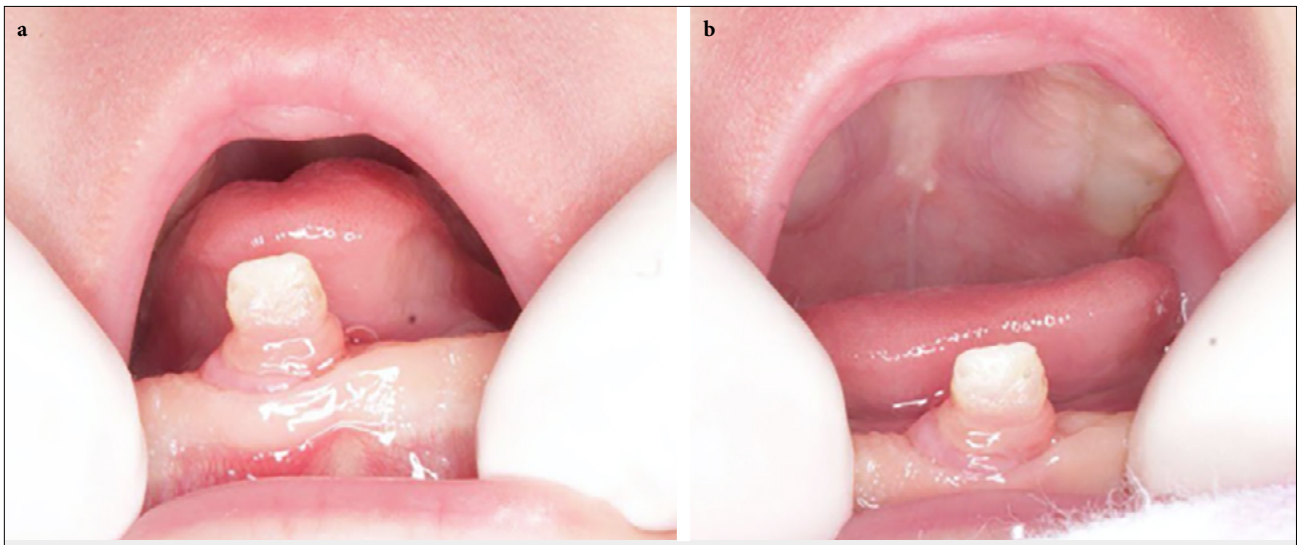

Figure 1. (a, b) Clinical appearance showing the presence of a neonatal tooth

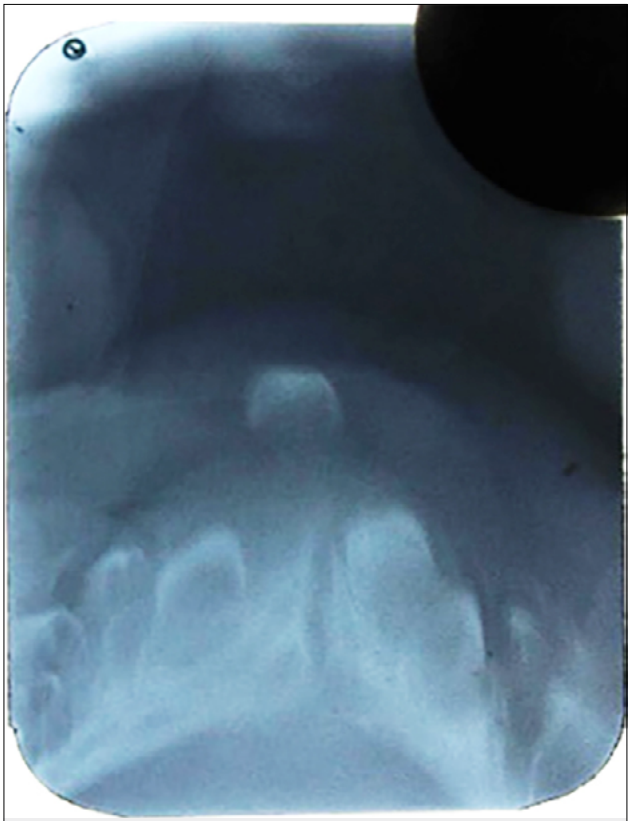

Figure 2. Radiographic exam showing the presence of a neonatal tooth compatible with the normal series. Absence of supernumerary teeth

with curved iris scissors, followed by removal of the remaining dental papilla with a Lucas No. 85 curette (Fig. 4a, b). The area was irrigated with sterile saline, and local hemostasis was achieved by compression with sterile gauze (Fig. 5). At the end of the procedure, the infant was breastfed to provide comfort and aid in local hemostasis.

During the 18-month clinical follow-up period, the absence of tooth 81 confirmed that the extracted tooth corresponded to the normal primary series. The eruption of teeth 71, 72, 74, 82, and 84 occurred without observable functional or aesthetic impairment. No systemic involvement or syndromic diagnoses were identified during the follow-up period (Fig. 6).

Although short- to medium-term follow-up provides valuable information on early childhood clinical outcomes, its limitations must be acknowledged. In particular, the absence of long-term monitoring and data prevents definitive conclusions regarding potential orthodontic implications in the permanent dentition, as well as possible esthetic or functional repercussions, which may only become evident as the child continues to develop.

Discussion

This study reports a clinical case of neonatal tooth loss (NTD) in a newborn, highlighting the importance of early diagnosis and timely intervention to mitigate the risks associated with accidental swallowing or aspiration of the tooth-events that can lead to serious complications and pose a risk to the patient's life. The clinical and radiographic findings supported the healthcare team's decision to extract, rather than retain, the tooth in the oral cavity.

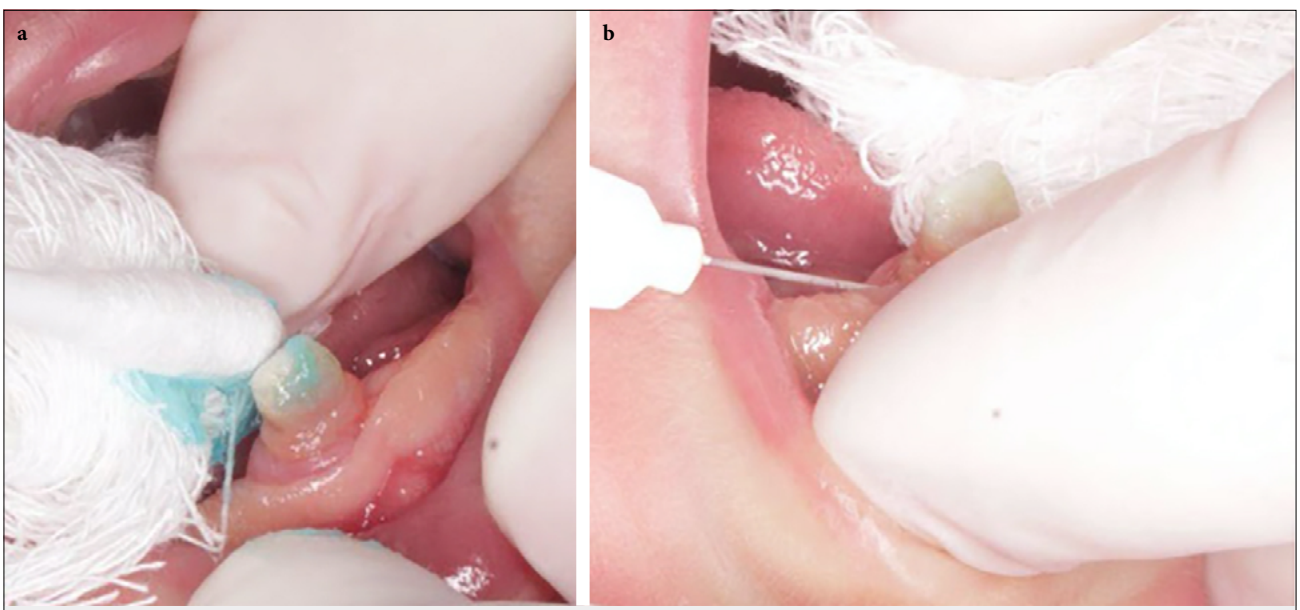

Figure 3. (a, b) Topical anesthesia with an anesthetic based on lidocaine andprilocaine, and terminal infiltrative anesthesia with an anesthetic based on lidocaine 2% and phenylephrine 1:100,000.



Figure 4. (a, b) Surgical removal of tooth 81, i.e., a neonatal tooth compatible with the normal series, with the aid of curved scissors and a fragment of the dental papilla.



Figure 5. The immediate clinical appearance after the removal of tooth 81



Figure 6. Clinical follow-up for 18 months showed the absence of tooth 81. Teeth 71, 72, 74, 82, and 84 erupted

Epidemiological studies have shown that, in approximately 85% of cases, the affected tooth is the mandibular central incisor, with approximately 95% of these teeth belonging to the normal deciduous dentition.[2,3,12] Furthermore, the literature indicates a higher prevalence of natal and neonatal teeth in female newborns.[11,13] In the present case, the patient's sex, the type of tooth affected, and its dental series were consistent with the patterns described in the literature.

The etiology of neonatal teeth remains unclear. The main hypotheses suggest factors such as superficial positioning of the tooth bud, hereditary influence, nutritional deficiencies,[11,14] and the presence of syndromes such as Ellis-van Creveld syndrome.[15] In particular, the occurrence of natal or neonatal teeth in the anterior maxillary region or the involvement of posterior teeth is often considered an indicator of a possible syndromic association.[16] In this case, the patient presented normal systemic conditions at birth and throughout the 18-month follow-up period, with no clinical signs suggestive of syndromic involvement. Furthermore, the legal guardians reported no family history of similar cases,

reinforcing the likelihood of isolated involvement due to the superficial position of the tooth bud.

Although conservative approaches are generally preferred, neonatal tooth extraction is indicated when its retention poses significant clinical risks.[7,11] In the reported case, several factors were observed that justified surgical conduct: tooth insertion in soft tissues, poor root development, marked mobility, potential risk of aspiration or accidental swallowing, and reported discomfort during breastfeeding. These findings alone contraindicate the retention of the tooth in the oral cavity.[3,6,7] Additionally, although no traumatic ulcers were observed in the maternal breast or on the ventral region of the newborn's tongue, Riga-Fede disease should be considered a possible complication in these cases[17] and is also a recognized indication for tooth extraction.[2,8,9] Therefore, given the patient's clinical signs and the tooth's unfavorable prognosis, extraction represented the safest and most appropriate course of action.

It is important to emphasize that tooth extraction in newborns should only be performed when the baby is at least 10 days old or has received a dose of vitamin K shortly after birth, in order to minimize the risk of bleeding associated with the procedure.[18]

Premature loss of primary teeth in cases of neonatal teeth can lead to significant aesthetic, orthodontic, and phonetic consequences. However, in this case, no aesthetic or functional impairments were observed during early childhood.[19] Gingival fibrosis can also occur in the edentulous region, potentially hindering the eruption of the permanent successor, thus reinforcing the need for long-term follow-up.[20]

Given these potential consequences, it is essential that clinicians be able to propose appropriate treatment alternatives that ensure dental rehabilitation, well-being, and quality of life for the patient. Furthermore, clinical and radiographic follow-up should be performed periodically, with careful monitoring of the formation and eruption of the permanent successor. However, in the present case, follow-up was limited to early childhood, which prevents the evaluation of long-term clinical outcomes related to permanent dentition.

Conclusion

Based on the clinical case presented, it is concluded that clinical and radiographic evaluation is essential for defining an individualized therapeutic approach in cases of neonatal teeth. Extraction has proven to be an effective and safe intervention when faced with health risks to the newborn, especially when there is severe mobility and hypoplastic structure. It is noteworthy that, even in the absence of visible lesions, these teeth can compromise breastfeeding and maternal and child well-being, which reinforces the importance of early diagnosis and evidence-based pediatric dentistry.

Disclosures

Ethics Committee Approval: This is a single case report, and therefore ethics committee approval was not required in accordance with institutional policies.

Informed Consent: Written informed consent was obtained from the patient for the publication of the case report and the accompanying images.

Conflict of Interest Statement: The authors have no conflicts of interest to declare.

Funding: The authors declared that this study received no financial support.

Use of AI for Writing Assistance: No AI technologies utilized.

Authorship Contributions: Concept – L.F.O.T.F., T.G., F.A.C.B.; Design – L.F.O.T.F., T.G., F.A.C.B.; Supervision – G.F.S., C.C.D.; Funding – NA; Materials – NA; Data collection and/or processing – L.F.O.T.F., T.G., G.F.S., C.C.D., F.A.C.B.; Data analysis and/or interpretation – L.F.O.T.F., T.G., G.F.S., C.C.D., F.A.C.B.; Literature search – L.F.O.T.F., T.G., G.F.S., C.C.D., F.A.C.B.; Writing – L.F.O.T.F., T.G., F.A.C.B.; Critical review – L.F.O.T.F., T.G., G.F.S., C.C.D., F.A.C.B.

Peer-review: Externally peer-reviewed.

References

1. Kariya P, Tandon S, Singh S, Tewari N. Polymorphism in emergence of deciduous dentition: A cross-sectional study of Indian children. J Investig Clin Dent 2018;9(1):e12266.
2. Cunha RF, Boer FA, Torriani DD, Frossard WT. Natal and neonatal teeth: Review of the literature. Pediatr Dent 2001;23(2):158–62.
3. Massler M, Savara BS. Natal and neonatal teeth: A review of 24 cases reported in the literature. J Pediatr 1950;36(3):349–59.
4. Vitali FC, Santos PS, Massignan C, Cardoso M, Maia LC, Paiva SM, et al. Worldwide prevalence of natal and neonatal teeth: Systematic review and meta-analysis. J Am Dent Assoc 2023;154(10):910–21.e4.
5. Bodenhoff J, Gorlin RJ. Natal and neonatal teeth: Folklore and fact. Pediatrics 1963;32:1087–93.
6. DeSeta M, Holden E, Siddik D, Bhujel N. Natal and neonatal teeth: A review and case series. Br Dent J 2022;232(7):449–53.
7. Varriano BM, Ades L, Vaughan SR. Case report: A rare case of bilateral molar natal teeth in a term newborn. Front Dent Med 2024;5:1336865.
8. Padmanabhan MY, Pandey RK, Aparna R, Radhakrishnan V. Neonatal sublingual traumatic ulceration: Case report & review of the literature. Dent Traumatol 2010;26(6):490.
9. Volpato LE, Simões CA, Simões F, Nespolo PA, Borges ÁH. Riga-Fede disease associated with natal teeth: Two different approaches in the same case. Case Rep Dent 2015;2015:234961.

10. Farsi DJ, Ahmed MM. Natal and neonatal teeth. Saudi Med J 2014;35(5):499–503.

11. Wang CH, Lin YT, Lin YJ. A survey of natal and neonatal teeth in newborn infants. J Formos Med Assoc 2017;116(3):193–6.

12. Galassi MS, Santos-Pinto L, Ramalho LT. Natal maxillary primary molars: Case report. J Clin Pediatr Dent 2004;29(1):41–4.

13. Mhaske S, Yuwanati MB, Mhaske A, Ragavendra R, Kamath K, Saawarn S. Natal and neonatal teeth: An overview of the literature. ISRN Pediatr 2013;2013:956269.

14. Bulut G, Bulut H, Ortac R. A comprehensive survey of natal and neonatal teeth in newborns. Niger J Clin Pract 2019;22(11):1489–94.

15. Ferraresso LFOT, Fagundes FAU, Padovese M, Singi P, Paiva MF, Inagaki-Nomura LT, et al. Peripheral odontogenic fibroma in a child with Ellis-van Creveld syndrome: Case report. Spec Care Dentist 2024;44(1):103–8.

16. El Khatib K, Abouchadi A, Nassih M, Rzin A, Jidal B, Danino A, et al. Natal teeth: Apropos of five cases. Rev Stomatol Chir Maxillofac [Article in French] 2005;106(6):325–7.

17. Slayton RL. Treatment alternatives for sublingual traumatic ulceration (Riga-Fede disease). Pediatr Dent 2000;22(5):413–4.

18. Centers for Disease Control and Prevention. What is vitamin K deficiency bleeding? Atlanta: CDC; 2025.

19. Volpato LE, Crivelli AS, Oliveira ET, Nobreza AM, Rosa A. Rehabilitation with esthetic functional fixed space maintainer: A report of two cases. Int J Clin Pediatr Dent 2021;14(2):315–8.

20. Ulson RCB, Corrêa MSNP, Lopes LD. Neonatal tooth: Case report. Rev Inst Cienc Saude [Article in Portuguese] 2008;26(1):130–4.